

# Management of patients undergoing hydroxychloroquine therapy

The quinolines, hydroxychloroquine (Plaquenil) and chloroquine are used primarily for their anti-inflammatory effects in the treatment of auto-immune conditions such as rheumatoid arthritis.

Another common use of these drugs is the prophylaxis and suppression of malaria. The use of quinolines may cause several ocular side-effects. The most significant complication is irreversible macular damage resulting in both visual acuity and visual field loss. However, the Royal College of Ophthalmologists (RCO) recently recommended against the monitoring of patients receiving quinoline therapy as it was deemed to be too costly, given the low incidence of retinal complications. In this article, we present a case of hydroxychloroquine retinopathy, describe the ocular changes associated with quinoline therapy, and recommend a review schedule for optometric patients who are currently taking these drugs. Furthermore, we recommend a proactive approach toward medical practitioners prescribing these drugs for optometric-based monitoring of these patients.

The quinolines, chloroquine and hydroxychloroquine (Plaquenil), are most commonly used in the treatment of

rheumatoid arthritis, systemic lupus erythematosus and cutaneous lupus, with recent studies establishing the efficacy of hydroxychloroquine in reducing the severity of pain, inflammation and disability in these conditions<sup>1,2</sup>. However, both drugs are associated with ocular side-effects.

Both chloroquine and hydroxychloroquine also act as effective anti-malarial agents, though current practice guidelines recommend the use of either low-dose hydroxychloroquine (less than 6.5mg/kg/day)<sup>3</sup> or mepacrine, as reports of ocular toxicity with these drugs are rare<sup>3,4</sup>. Chloroquine, however, is associated with a far greater incidence of irreversible ocular toxicity and is generally only considered when other treatment options have failed<sup>5</sup>.

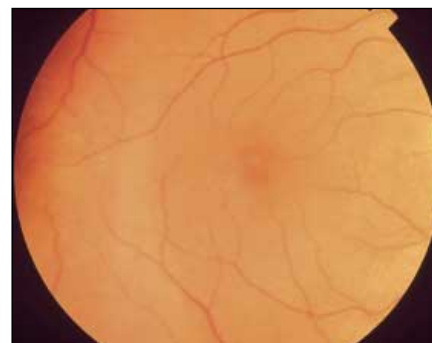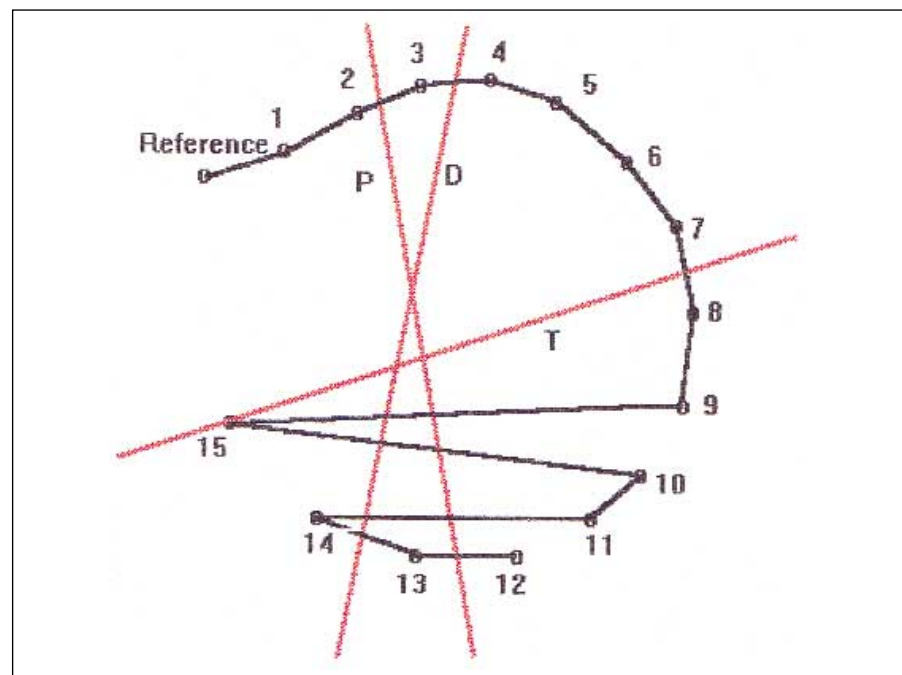
## Case report

A 54-year-old female presented with reduced visual acuity in the right eye (RE), which had been noted for several weeks. The left eye (LE) was reported as normal. The patient was being treated for rheumatoid arthritis and had been taking 1 tablet (200 mg) of hydroxychloroquine daily for 3 years. This dose is well below the maximum safe daily dosage, as recommended by the RCO<sup>3</sup>.

Corrected visual acuities were 6/9 RE with no improvement with pinhole and 6/4.8 LE. Pelli-Robson contrast sensitivities were 1.60

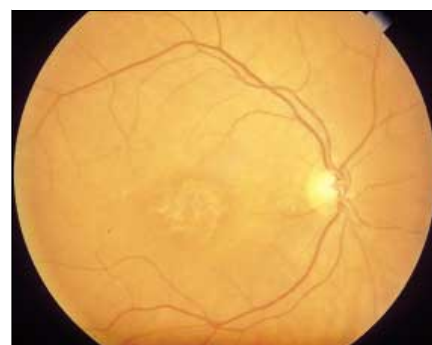**Figure 1**

Farnsworth Panel D-15 arrangement for the left eye showing three crossings of blue-yellow confusion



**Figure 2**

Early retinopathy due to hydroxychloroquine with areas of depigmentation



**Figure 3**

"Bulls-Eye" maculopathy from chloroquine toxicity showing the concentric rings of pigmentation on depigmentation

and 1.70 log CS, respectively. Assessment of colour vision, using the D15 panel, revealed a blue-yellow defect in the right eye only (Figure 1). Fundus examination revealed stippling of the RPE and several regions of both hyperpigmentation and depigmentation in the right eye (Figure 2). The left fundus was free of any pigmentary changes. Neither cornea showed any sign of corneal epithelial changes. Neither fundus showed peripheral pigmentary change.

The patient was referred back to her rheumatologist and use of the drug was discontinued. The observed RPE disturbances and associated visual loss remained at follow-up, 6 months later.

## Clinical features of quinoline-related ocular toxicity

The toxic ocular effects of quinoline therapy were first reported in 1958<sup>5</sup> by Hobbs and reviewed by Collin<sup>6</sup> in 1962. They may be either reversible and asymptomatic, requiring no change in management, or irreversible and symptomatic, usually resulting in

cessation of the therapy with these drugs.

As with chloroquine, the most severe ocular complication of hydroxychloroquine treatment is maculopathy<sup>7</sup>. However, hydroxychloroquine appears to be less toxic than chloroquine. Early stippling of the RPE is typically followed by the occurrence of fine granular macular pigmentation and loss of the normal foveal reflex<sup>8</sup>. These changes which tend to form a circular pattern (**Figure 3**) may progress to the classical bull's eye maculopathy (**Figures 4 and 5**). This condition involves the formation of concentric zones of hyperpigmentation and depigmentation (with a hyperpigmented zone beneath the fovea)<sup>9</sup>. Advanced retinopathy may follow, including widespread pigmentary changes, optic atrophy and arteriolar attenuation<sup>10</sup>.

Generalised visual disturbances, difficulty with fixation and, rarely, a scotoma to white targets may develop in association with, and possibly even prior to, the early fundus changes<sup>11,12</sup>. Visual field defects correlate with the severity of the above-mentioned fundus changes<sup>13,14</sup>. However, prior to any retinal changes, a small paracentral (between 4 and 9 degrees from fixation) scotoma to a red target may develop<sup>15</sup>. Following the onset of Bull's eye maculopathy, central scotomata to white light and peripheral field constriction can occur<sup>14</sup>. It is yet to be seen whether more sensitive methods of perimetry (such as flicker or blue-yellow protocols), which have proven useful for other conditions, would identify field defects any earlier than standard methods permit.

Advanced maculopathy is accompanied by diminished visual acuity<sup>16</sup> and colour vision defects<sup>17</sup>. In the early stages, even in a patient with significant pigmentary change, the full-field electroretinogram may have normal photopic voltages and latency<sup>18</sup>. As the retinopathy progresses peripherally, dark adaptation is affected and a subnormal ERG indicates a greater loss of cones than rods<sup>13,8</sup>. The usual field loss is central<sup>15</sup> but an often overlooked finding is a peripheral pigmentary retinopathy (**Figure 6**) with an associated peripheral visual field loss, occasionally leading to a mistaken diagnosis of retinitis pigmentosa or cone-rod dystrophy<sup>17</sup>.

Corneal verticillata or "vortex keratopathy" in which greyish or golden corneal epithelial deposits appear in a vortex pattern is the other common side-effect of quinoline therapy. These deposits begin as individual white deposits but later become pigmented and yellowish<sup>5,19</sup>. Later, there are yellowish curved lines in the typical vortex pattern<sup>20,21</sup>.

These deposits are not the drug itself, but rather lipid inclusions which are also seen with amioderone and chlorpromazine use, and in the lysosomal storage diseases such as Fabry's disease<sup>22,23</sup>. They all have a

common pathophysiology of causing binding of anionic phospholipids of lysosomal membranes and the promotion of intracellular inclusions<sup>23</sup>. The appearance of the keratopathy is not dose-related and is not correlated with the development of subsequent retinopathy<sup>21</sup>. Remission usually follows cessation of therapy, although spontaneous resolution is possible<sup>21</sup>. These deposits are asymptomatic, except in rare cases when they become dense enough to cause haloes and impaired vision<sup>24</sup>.

Disturbances of accommodation and extra-ocular muscle palsies have been associated with quinoline therapy, but are rare and transient<sup>25</sup>. In addition, adverse reactions involving the skin and gastro-intestinal tract may coincide with the use of hydroxychloroquine and chloroquine. Non-specific complaints such as headache, vertigo and muscle weakness may also occur<sup>25</sup>.

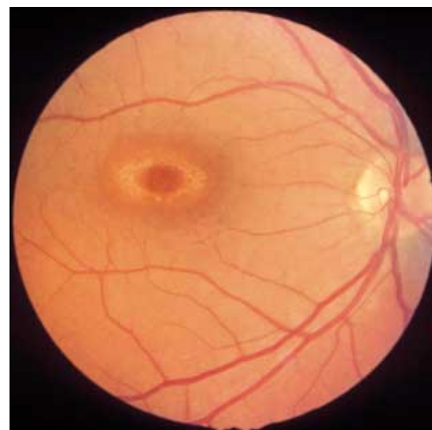
Following chloroquine therapy, marked bleaching of hair<sup>26, 27</sup> may occur. Eyebrows, eyelashes and axillary and pubic hair may be affected<sup>28</sup>. In some cases, the hair may fluoresce with ultraviolet light<sup>28</sup>.

The progression of quinoline retinopathy is variable and unpredictable, but development of retinal lesions is typically progressive – especially where treatment is continued – and often up to three years after cessation of drug use<sup>13,10</sup>. Progression of retinopathy after cessation of treatment is more likely if the retinopathy is advanced, conversely retinopathy is more likely to resolve if treatment ceases during the early stages of retinopathy<sup>29,30</sup>. Interestingly, the onset of retinopathy has been observed up to 5 years after quinoline treatment has finished<sup>31,11</sup>. Nevertheless, the prognosis is strongly dependent on detection of early changes, particularly macular pigment disturbance<sup>8</sup>. Therefore, it is important for optometrists as primary eye care practitioners and, when screening patients for rheumatologists, to recognise these changes in order for modifications to therapy to be made, if appropriate, and the extent of visual loss minimised.

### Pathophysiology

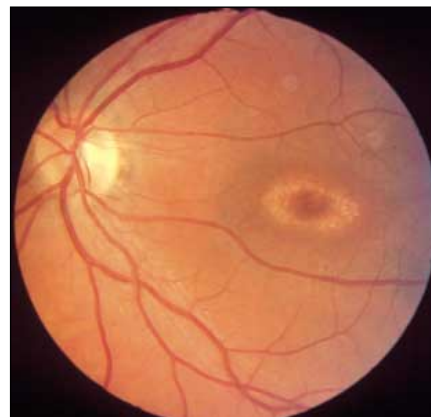While the precise mechanism of their anti-inflammatory effect is not understood, quinolines are known to interact with cellular components, such as nucleic acids and melanin<sup>32,7</sup>. Thus, the quinolines become concentrated in the melanin-containing structures of the eye such as the iris and retinal pigment epithelium.

Quinolines exert their toxic effect upon both the RPE and directly on the photoreceptors<sup>6</sup>. The earliest histopathological change, even before the RPE damage, appears to be membranous cytoplasmic bodies in ganglion cells and degenerative changes in photoreceptor outer segments<sup>17</sup>. Chloroquine has been shown to



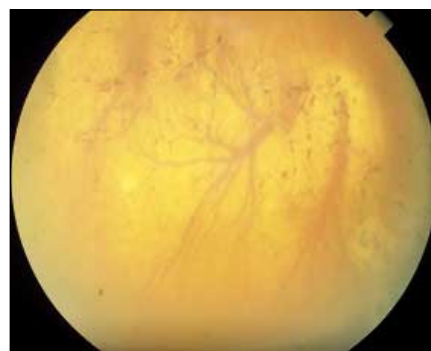**Figure 4**

Advanced bulls eye retinopathy of right eye of patient receiving long-term chloroquine therapy



**Figure 5**

Advanced bulls eye retinopathy of left eye of patient receiving long-term chloroquine therapy



**Figure 6**

Advanced chloroquine retinopathy demonstrating a pseudo-retinitis pigmentosa appearance of bone-spicule pigment clumping

cause swelling in the pigmented cells, reduction in melanin concentration and a decrease in the activity of several dehydrogenase enzymes<sup>33</sup>. Other studies indicate that chloroquine destroys or inhibits oxidative enzymes within the ellipsoids of

the inner segment<sup>24</sup>. Loss of both rods and cones is followed by pigment migration into the outer retinal layers, though the inner retina remains intact<sup>3</sup>. Hence, it is likely that quinolines diminish the effectiveness of both the regulatory mechanisms of the retina and RPE, and the photo-protective melanin-containing RPE cells.

A factor that adds to the toxicity of chloroquine and hydroxychloroquine is their very slow excretion rate. Small amounts of chloroquine are detectable in blood and urine as long as five years after the drug is discontinued<sup>17</sup>. This prolonged retention may account for reports of progressive and delayed-onset retinopathy despite discontinuation of therapy<sup>17</sup>.

## Discussion

Ocular toxicity subsequent to hydroxychloroquine treatment is uncommon. As an indication of the rarity of this condition, we are aware of only 29 published incidences since 1968<sup>9,4,3,18,35</sup>. Furthermore, several prospective studies have addressed the issue of prevalence, with a total of 2 cases of retinopathy observed in 2707 patients receiving the drug<sup>36,37,38,39,40,41,42</sup>. Most of the reported cases were observed in patients receiving doses higher than the current recommended maximum (6.5mg/kg/day). Importantly, in those patients exhibiting toxic effects and taking less than the recommended safe dosage, the overwhelming majority had cumulative doses of greater than 200g<sup>43</sup>.

This is consistent with the proposal of Mills, Beck and Power<sup>44</sup> who suggested that maculopathy is unlikely to develop in patients with normal fundi prior to treatment, provided a cumulative dose of approximately 200g is not exceeded. In support of this suggestion that patients with normal fundi may have a greater tolerance to hydroxychloroquine, Johnson and Vine<sup>45</sup> reported that no retinopathy was found in nine patients with cumulative doses ranging from 1,054g to 3923g. In the case reported here, the cumulative dose was 200g – serving as some justification for the suggestion of Mills et al (1981) that eye examinations should be conducted at each

**Table 1**

Suggested examination frequency listed by daily dosage. This is based approximately on intervals of cumulative dose of 100g.

Daily dosage (mg; 1 tablet = 200mg)	Examination frequency (months)
100	24-36
200	18
300	12
400	9
600	6

100g of cumulative treatment<sup>44</sup>.

Despite the infrequency of complications, the manufacturer of hydroxychloroquine recommends an initial ophthalmic examination prior to therapy and subsequent 6-monthly monitoring<sup>25</sup>. Temporary cessation of treatment is suggested at the appearance of any corneal changes and complete withdrawal of the drug following the detection of any fundus signs or visual field defects<sup>25</sup>.

Mills, Beck and Power<sup>44</sup> doubted whether routine visual field screening was justified, and suggested that careful ophthalmoscopy appeared to be the most effective test, but, Bernstein<sup>9</sup> included in his definition of hydroxychloroquine retinopathy the presence and persistence of paracentral or central visual field scotomata to supra-threshold white stimuli.

Given the low incidence of quinoline-related ocular toxicity, the Royal College of Ophthalmologists (RCO) found there was no evidence-based justification for an ocular toxicity screening programme<sup>3</sup>. Furthermore, they described any such screening programmes as costly and as generating needless anxiety for patients and unnecessary work for clinicians. Despite this, the RCO have suggested an annual evaluation (by the prescribing medical practitioner) of visual acuity and referral for ocular examination in the presence of any loss.

According to RCO, the ocular examination should include:

- Distance and near acuity measurement
- Colour vision assessment
- Visual field assessment (automated perimetry)
- Corneal biomicroscopy
- Mydriatic fundus examination

As these may all be components of a routine optometric examination, optometrists are ideally suited to monitor patients receiving hydroxychloroquine therapy in a thorough and cost-effective manner. The advent of automated perimeters with rapid testing paradigms facilitates the inclusion of visual field testing in a routine examination protocol for patients receiving hydroxychloroquine treatment.

The authors concur with the advice of Mills, Beck and Power<sup>44</sup> that patients receiving hydroxychloroquine therapy should be monitored every 100g of cumulative dose. **Table 1** gives the suggested examination frequency according to dosage.

Finally, the authors recommend a proactive awareness campaign directed at the prescribing medical practitioner. Optometrists possess the necessary skill and equipment to monitor these patients efficiently and cost-effectively. To reduce the risk of irreversible visual loss, prescribing practitioners should be

encouraged to refer patients to optometrists for review at 100g cumulative dose intervals.

## About the authors

Harrison Weisinger is supported by an NHMRC Australian Part-Time Research Fellowship and is based at the Royal Melbourne Institute of Technology University.

Konrad Pesudovs is supported by an NHMRC Sir Neil Hamilton Fairley Research Fellowship. He is based at the University of Bradford.

H. Barry Collin is Professor Emeritus at the University of New South Wales and Professorial Fellow at the University of Melbourne.

## Corresponding Author

Dr Konrad Pesudovs, Department of Optometry, University of Bradford, Bradford, West Yorkshire, BD7 1DP  
Email: K.Pesudovs@bradford.ac.uk  
Fax: 01274-235570  
Tel : 01274-236239

## References

1. HERA. A randomized trial of chloroquine in early rheumatoid arthritis: the HERA study. *Am J Med* 1995;98:156-168.
2. Silman A, Shipley M. Ophthalmological monitoring for hydroxychloroquine toxicity: a scientific review of available data. *Br J Rheumatol* 1997;36:599-601.
3. Fielder A, Graham E, Jones S, Silman A, Tullo A. Royal College of Ophthalmologists guidelines: Ocular toxicity and hydroxychloroquine. *Eye* 1998;12(6):907-909.
4. Tokumaru GK. New considerations in monitoring for hydroxychloroquine retinopathy. *Clin Eye Vis Care* 1996;8:99-104.
5. Hobbs HE, Calnan CD. The ocular complications of chloroquine therapy. *Lancet* 1958;1(June):1207.
6. Collin HB. The ocular complications of chloroquine therapy. *Aust J Optom* 1962;45?:322-5.
7. Aylward JM. Hydroxychloroquine and chloroquine: assessing the risk of retinal toxicity. *J Am Optom Assoc* 1993;64:787-797.
8. Michaelson IC. Retinal degenerations. In: Michaelson IC, editor. *Textbook of the Fundus of the Eye*. Edinburgh: *Churchill Livingstone*; 1980. 406-434.
9. Bernstein HN. Ocular safety of hydroxychloroquine sulfate (Plaquenil). *Southern Med J* 1992;85(3):274-279.
10. Hobbs HE. Eye changes with chloroquine. *BMJ* 1966;1:1109.
11. Easterbrook M. Long-term course of anti-malarial maculopathy after cessation of treatment. *Can J*

- Ophthalmol* 1992;27(5):237-239.
12. Easterbrook M. The long-term safety of hydroxychloroquine. *Sem Arthritis Rheum* 1993;23(2(Suppl)):62-67.
  13. Okun E, Gouras P, Bernstein HN, Von Sallmann L. Chloroquine retinopathy: a report of eight cases with ERG and dark adaptation findings. *Arch Ophthalmol* 1963;69:59-71.
  14. Hart WMJ, Burde RM, Johnston GP, Drews RC. Static perimetry in chloroquine retinopathy: perifoveal patterns of visual field depression. *Arch Ophthalmol* 1984;102(3):377-380.
  15. Hansen E. Chloroquine retinopathy evaluated with colour perimetry. *Ann Ther Clin Ophthalmol* 1974;25:323-331.
  16. Shearer RV, Dubois EL. Ocular changes induced by long-term hydroxychloroquine (Plaquenil) therapy. *Am J Ophthalmol* 1967;64(2):245-252.
  17. Schachat AP, Murphy RB, Patz A. Medical Retina. In: Ryan SJ, editor. *Retina*. St Louis: CV Mosby; 1989. 742-4.
  18. Maturi RK, Folk JC, Nichols B, Oetting TT, Kardon R. Hydroxychloroquine retinopathy. *Arch Ophthalmol* 1999;117:1262-3.
  19. Rebello DJA. Ocular reactions to antimalarial drugs. *Arch Dermatol* 1961;83:785-9.
  20. Hobbs HE, Calnan CD. Visual disturbances with antimalarial drugs with particular reference to chloroquine keratopathy. *Arch Dermatol* 1959;80:557-563.
  21. Hobbs HE, Eadie SP, Somerville F. Ocular lesions after treatment with chloroquine. *Br J Ophthalmol* 1961;45:284-297.
  22. Collin HB, Penry VF. The ocular manifestations of Fabry's disease: A family study. *Aust J Optom* 1983;66:173-7.
  23. Vinals AF, Kenyon KR. Corneal manifestations of metabolic diseases. *Int Ophthalmol Clin* 1998;38(1):141-153.
  24. Biard L, Perdriel G, Chevaleraud J, Vignat J-P. Diagnostic problems in chloroquine central retinopathy. *Bul Soc Ophthalmol Fr* 1973;73:539-544.
  25. Kaswell A. MIMS Annual. Australian edition 22nd ed. Singapore: Tien Wah Press; 1998.
  26. Fuld H. Retinopathy following chloroquine therapy. *Lancet* 1959;2(617-619).
  27. Mayer W. Chloroquine retinopathy. *Am J Ophthalmol* 1962;53:769-774.
  28. Dall LJC, Keane JA. Disturbances of pigmentation with chloroquine. *BMJ* 1959;1387-9.
  29. Brinkley JR, Dubois EL, Ryan SJ. Long-term course of chloroquine retinopathy after cessation of medication. *Am J Ophthalmol* 1979;88(1):1-11.
  30. Crews SJ, Cantab MB. Chloroquine retinopathy with recovery in early stages. *Lancet* 1964;2:436-438.
  31. Burns RP. Delayed chloroquine retinopathy. *N Eng J Med* 1966;275:693-696.
  32. Bernstein HN, Zvaifler N, Rubin M, Mansour AM. Ocular deposition of chloroquine. *Invest Ophthalmol Vis Sci* 1963;2(4):384-392.
  33. Meier-Ruge W. Experimental investigation of the morphogenesis of chloroquine retinopathy. *Arch Ophthalmol* 1965;73:540-544.
  34. Yanoff M, Tsou K-C. A tetrazolium study of the whole eye. Effect of chloroquine in the incubation medium. *Am J Ophthalmol* 1965;59:808-810.
  35. Thorne JE, Maguire AM. Retinopathy after long-term standard doses of hydroxychloroquine. *Br J Ophthalmol* 1999;83:1201-2.
  36. Rynes RI, Krohel G, Falbo A, Reinecke RD, Wolfe B, Bartholomew LE. Ophthalmological safety of long-term hydroxychloroquine treatment. *Arthritis Rheum* 1979;22:832-836.
  37. Tobin DR, Krohel GB, Rynes RI. Hydroxychloroquine - seven year experience. *Arch Ophthalmol* 1982;100:81-83.
  38. Mantyjarvi M. Hydroxychloroquine treatment and the eye. *Scand J Rheumatol* 1985;14:171-174.
  39. Morsman CDG, Livesey SJ, Richards IM, Jessop JD, Mills PV. Screening for hydroxychloroquine retinal toxicity. Is it necessary? *Eye* 1990;4(4):572-576.
  40. Arden GB, Kolb H. Antimalarial therapy and early retinal change in patients with rheumatoid arthritis. *BMJ* 1966;1:270-273.
  41. Nylander U. Ocular damage in chloroquine therapy. *Acta Ophthalmol* 1996;44:335-347.
  42. Levy GD, Munz SJ, Paschal J, Cohen HB, Pince KJ, Peterson T. Incidence of hydroxychloroquine retinopathy in 1207 patients in a large multicentre outpatient practice. *Arthritis Rheum* 1997;40(8):1482-1486.
  43. Mavrikakis M, Papazoglou S, Sfrikakis PP, Vaiopoulos G, Rougas K. Retinal toxicity in long term hydroxychloroquine treatment. *Ann Rheum Dis* 1996;55(3):187-189.
  44. Mills PV, Beck M, Power BJ. Assessment of the retinal toxicity of hydroxychloroquine. *Trans Ophthalmol Soc UK* 1981;101:109-113.
  45. Johnson MW, Vine AK. Hydroxychloroquine therapy in massive total doses without retinal toxicity. *Am J Ophthalmol* 1987;104:139-144.

## Acknowledgements

The authors would like to thank Wendy Laffer and Angela Chappell of the Department of Ophthalmology, Flinders Medical Centre for editorial assistance and photography (Figures 2,3 & 6) respectively. The source of Figures 4 and 5 from H. Barry Collin is unknown. Although it is known that the patient was on long-term chloroquine therapy, the complete clinical records are not available.